

FEATURES OF THE APPLICATION OF AUTOLOGICAL MESENCHYMAL STEM CELLS IN THE TREATMENT OF SYMPTOMATIC EPILEPSY, A CLINICAL CASE

FEDOR KHLEBOKAZOV¹, TATSIANA DAKUKINA¹, MIHAIL POTAPNEV²,
SVETLANA KOSMACHEVA², NATALIA PARAMONOVA², NIKOLAI MISYUK¹,
ELENA SLOBINA¹, IVAN HLAVINSKI¹

¹Republican Research and Practical Mental Health Center, Minsk, Belarus

²Republican Scientific and Practical Center for Transfusiology and Medical Biotechnology, Minsk, Belarus

E-mail: polak0208@mail.ru

Abstract

Pharmacological-resistant epilepsy cases require alternative therapies. A modern high-tech method of treating symptomatic epilepsy has been developed and successfully applied in Belarus. This is the transplantation of autologous mesenchymal bone marrow stem cells, which can be obtained in sufficiently large quantities and set the direction of their differentiation into neurons.

Below is a description of a clinical case of a 24 year old patient with epilepsy. The patient has secondary generalized tonic-clonic and tonic convulsive seizures due to perinatal pathology of with the history of developed pharmacoresistance to antiepileptic drugs. Treatment with autologous mesenchymal bone marrow stem cells significantly improved the patient's condition: generalized tonic-clonic and tonic seizures stopped. After the repeated administration of autologous mesenchymal bone marrow stem cells stable clinical remission was achieved. It can be assumed that treatment with autologous mesenchymal stem cells helps to overcome resistance to antiepileptic drug therapy.

Key words: epilepsy, pharmacological, resistance, stem cells

DOI: 10.19260/PJAS.2020.6.2.07

With the rapid development of neuropharmacology, the principles of epilepsy treatment has changed significantly, which made it possible to achieve stable remission in 70 - 75% of patients [4]. At the same time, when all the conditions of antiepileptic treatment are fulfilled, some patients with drug-resistant epilepsy are not able to achieve satisfactory correction [2]. Surgical intervention in these patients is not always indicated, since, with a history of many years of unsuccessful intake of antiepileptic drugs, they have developed complex epileptic systems, including several epileptic foci, when its leading role is removed, it subsequently passes to another and seizures resume [6]. Therefore, at present, in the management of patients with drug-resistant epilepsy, great importance is attached to combining therapy using a new drug and other methods of exposure. One of these methods is the transplantation of autologous mesenchymal bone marrow stem cells (AMSC BM), which can be obtained in sufficiently large quantities and set the direction of their differentiation into neurons [1, 3, 5, 7, 8].

Below is a description of a clinical case of the successful treatment of a patient with drug-resistant epilepsy. Patient S., 24 years old, was repeatedly examined and treated at the "Republican Scientific and Practical Center for Mental

Health". Heredity is not psychopathologically burdened. She was born on time as the only child in the family, with strabismus, and operated on. She grew and developed normally. She went to school at the age of 6. She graduated from the 11 year of secondary school. She entered the Vitebsk State University at the Faculty of Social Pedagogy and Psychology, and was a 5th year student. Due to illness, she was on academic leave. She is unmarried and has no children. She lives with her parents. Allergic anamnesis is not burdened. From the transferred diseases: colds, chicken pox.

She has been ill since 2014. She associates the onset of seizures with the fear of a firecracker going off. History - perinatal pathology (childbirth with forceps, there is a deformation of the parietal region on the left measuring 9 x 3 cm) found. on an MRI of the brain from 13/02/2017. Diffuse cerebral subatrophy is visualized. The lateral ventricles are slightly dilated, asymmetric S> D. The hippocampus is asymmetric (D> S), and the volume on the left is reduced. There is deformation of the soft tissues of the skull on the left (Fig. 7). The seizures began with a simple partial motor in the form of clonic twitching of the facial muscles of the face and lips. Then the patient lost consciousness, generalized tonic-clonic or tonic convulsions,

salivation, and sometimes tongue bites were noted. The frequency was 8-10-13 seizures per month. Myoclonus of arms and legs was observed once - twice a month (serially). During hospitalization from 2/01/2017. to 03/14/2017 the department registered 19 generalized tonic-clonic and 8 generalized tonic seizures while taking antiepileptic drugs.

A consultation was held, where the expediency of treating AMSC BM was established. Autotransplantation of AMSC KM was carried out under aseptic conditions in two stages: by intravenous and endolumbar administration of AMSC KM.

On the EEG from 01/13/2017 (before the AMSC KM transplantation), patient S. has an irregular alpha rhythm with a peak frequency of 10.5 Hz. The frequency-spatial structure of the alpha rhythm is pathologically perverted (Fig. 1). The structure of the maximum values of the average coherence is presented in the form of a triangle in the frontal-central regions (Fig. 2), which is typical for an active epileptic process. There is a moderate increase in low diffuse beta and theta activity. Epileptiform activity in the form of spikes, the frequency of which reaches 30 per minute, which is recorded in large quantities in the left frontotemporal region (Fig. 3). There are also rare discharges of high, sharp, bilaterally synchronous alpha waves with a frequency of 1-2 per minute.

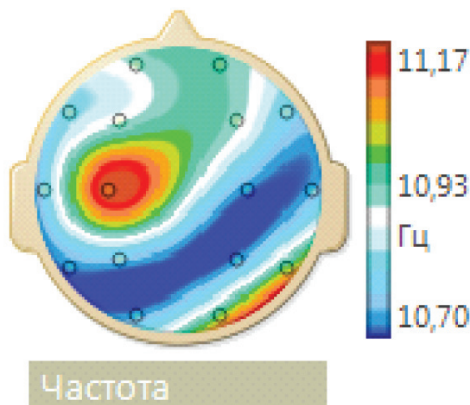


Fig. 1: Pathological inversion of the frequency-spatial structure of the alpha rhythm (the minimum frequency values are located not in the frontal, but in the parietal regions).

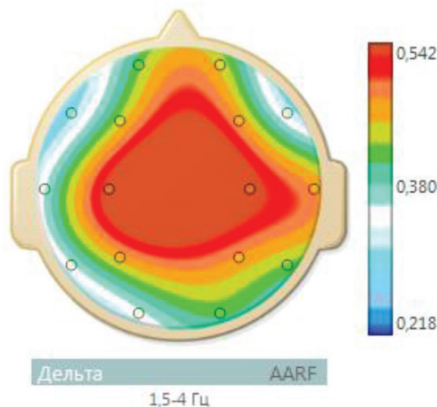


Fig. 2: The maximum values of the mean coherence are presented in the form of a triangle in the frontal-central regions.

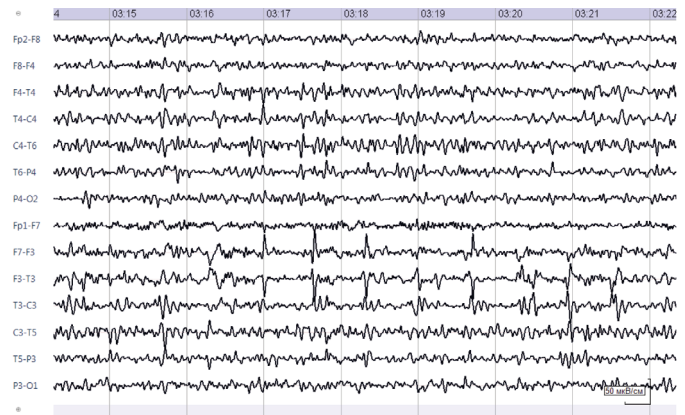

Fig. 3: Adhesions in the left frontotemporal region.

After the first course of stem cell injection on the EEG from 03/14/2017, the amount of epileptiform activity significantly decreased. The frequency of spikes in the left temporal region decreased from 30 to 2 per minute, the frequency of bilaterally synchronous discharges of acute alpha waves remained at the level of 1-2 per minute. At a frequency of the alpha rhythm of 10.5 Hz, its frequency-spatial structure was normalized, but the structure of the maximum values of the average coherence was still presented in the form of a triangle, which indicated the presence of an active epileptic process.

Upon admission (09/14/2017 - 10/10/2017) associated with the repeated course of administration of AMSC KM, 7 generalized tonic seizures were registered in the department (the increase is associated with the absence of Levipil); the frequency at home was up to 4 - 5 generalized tonic seizures per month, while taking antiepileptic drugs.

After repeated transplantation of AMSC KM, generalized seizures stopped. The remission lasted over 10 months. Then, during the next 3 years, the patient had generalized tonic seizures with a frequency of up to 1 in 1-2 months and simple partial motor seizures in the form of tonic convulsions of the facial muscles of the face and lips up to 2 times a month.

The patient recovered at the university and graduated. She worked as a teacher in a gymnasium and got married.

No paroxysmal activity was recorded on the EEG from 02/01/2018 after the second course of stem cell injections. The EEG retained a disorganized alpha rhythm with a peak frequency of 12.5 Hz with a diffuse increase in beta activity. Its frequency-spatial structure was largely normalized and did not go beyond the norm. There was also a reduction in the pathological structure of the maximum values of the average coherence in the form of a triangle (Fig. 4-6).

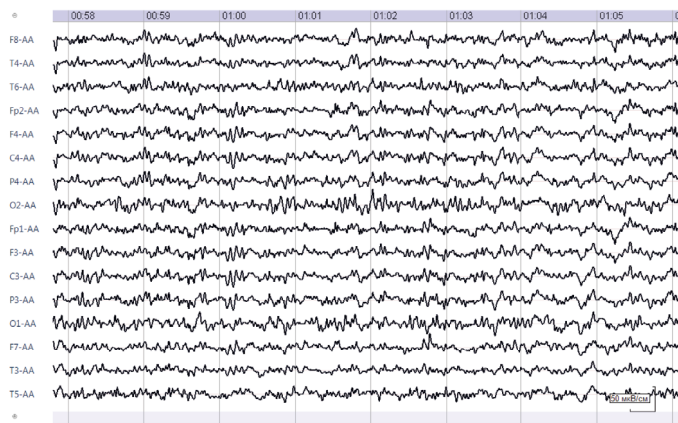


Fig. 4: EEG after re-implantation of stem cells.

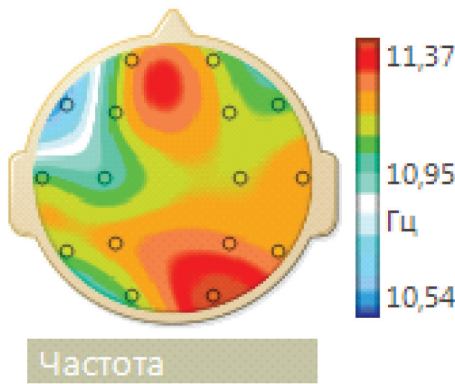


Fig.5: Frequency-spatial structure of the alpha rhythm with a tendency to normalization (the alpha rhythm of the maximum frequency is located mainly in the occipital region, and the minimum frequency - in the frontal region)

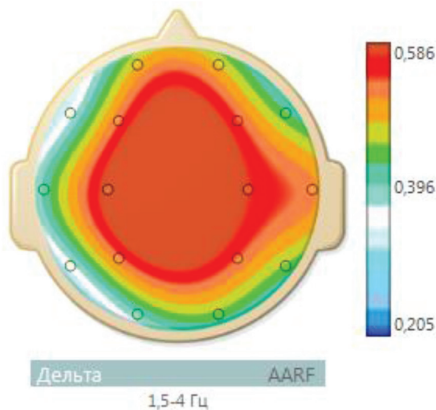


Fig. 6: Reduction of the pathological structure of coherence in the form of an "epileptic triangle" (the maximum values of the average coherence are presented in the form of a diamond).

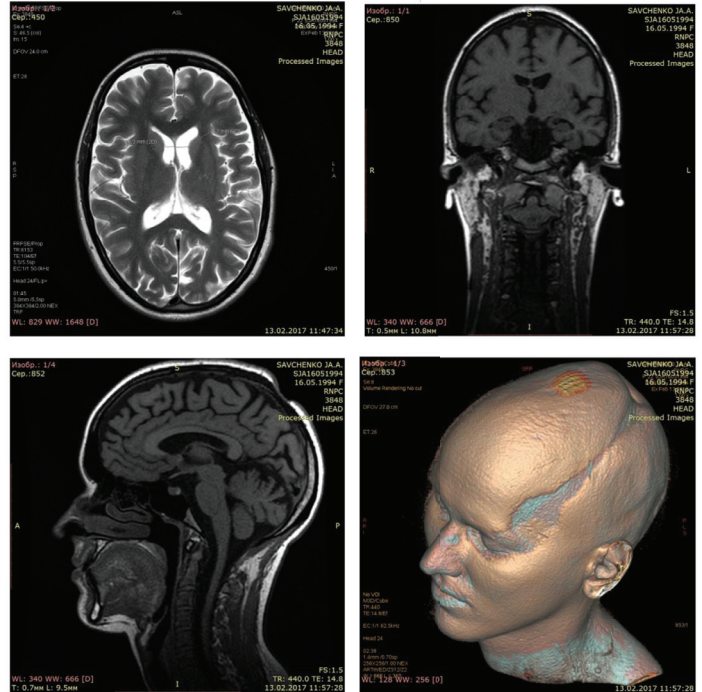


Fig. 7: MRI from 13.02.2017. the brain of patient S.

In PET CT examination of the brain with a radiopharmaceutical F18 - fluorodeoxyglucose, which was carried out on 29/03/2017. After the first course of administration of AMSC KM, a picture of a pronounced decrease in the metabolic activity of the left hemisphere of the brain was revealed. There was a significant decrease in the fixation of the radiopharmaceutical in the left frontal, parietal, temporal and occipital lobes.

In order to assess the functional state of the brain based on metabolic activity data, a repeated PET CT scan was performed on 7/02/2018 five months after the second course of AMSC KM administration. The data obtained on the metabolism of the radiopharmaceutical over time and when compared with the relative reference regions indicate an increase in metabolic activity in the zones concerned: in the left parietal, temporal and occipital lobes (Fig. 8). The control PET CT study was performed under identical conditions, which is a mandatory requirement for assessing the dynamics (the study was carried out on the same scanner, with the same injected activity, observing the time parameters of the study protocol).

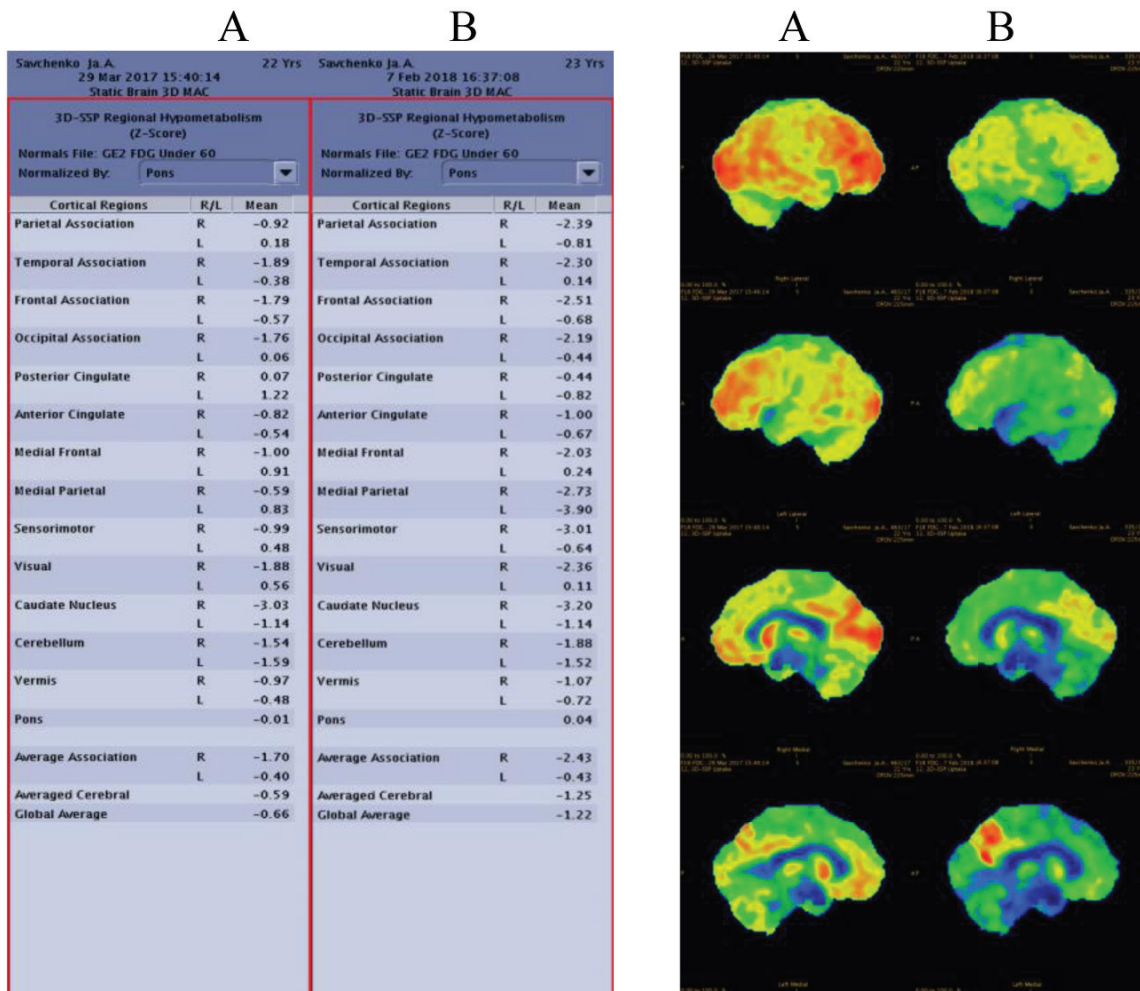


Fig. 8: Results of brain examination of patient S. by PET CT with F18 fluorodeoxyglucose radiopharmaceutical in dynamics

A - after the first course of administration of AMSC KM
 B - after the second course of administration of AMSC KM

Thus, as a result of re-implantation of stem cells, a significant improvement in both the clinical picture and the data of the visual and computer EEG was achieved.

Psychological research: Examination before the first course of AMSC BM revealed mild cognitive impairments.

Interested in research results she was. tense doing some tasks and. experienced difficulties in counting operations, in the serial account she scored only 2 points, explaining this as "difficulty with mathematics." Recalling 3 words she named one wrong (instead of a bus she named a car).

There was a slight exhaustion of mental processes, and a moderate decrease in work efficiency. Her working capacity was slightly slowed down with good mental stability.

No pronounced violations of mnestic functions were revealed. The volume of short-term mechanical memory was good. The retention of information was solid. Her information load was slightly reduced.

When performing the method "Excluding objects", she coped well with the first half of the rows, using an essential feature. Then there was a decrease in the speed of test

execution and a decrease in the level of generalization, she could not always name the group. So, the patient excluded the pistol, and the rest of the items were combined into the group "safe (cap, drum and umbrella)"; "Airplane, steamer, car, balloon" – the patient excluded the balloon, explaining: "the rest of the items are advanced technology".

The results revealed moderate personal anxiety and low situational anxiety. The level of depression was within normal limits.

A tendency towards three types of character accentuation was found in the personality structure: emotive, exalted and demonstrative. These features are characterized by an increased ability to repress, and the ease of transition from a state of joy to a state of sadness. The patient is prone to impressionability and sensitivity.

During the repeated psychological examination in March 2018, after the second course of the introduction of AMSC KM, the functioning of the patient's working memory improved, that is, it approached normal levels. Significant differences were observed immediately after combined treatment. Attention throughout the task remained stable before and after the combined administration of AMSC CM. The level of functioning of cognitive processes remained

stable. There were no significant changes in the level of hospital anxiety. In the study of long-term memory, performance, hospital depression and anxiety in the patient, no statistically significant changes were found before nor after the combined administration of AMSC BM.

Mental status: Consciousness was clear, in place, time and self was oriented correctly. The background of the mood was unstable, emotionally labile. The patient in the conversation was verbose, detailed, somewhat tense, anxious. Attention was steady. The criticism of the disease has been preserved. Acute psychotic disorders have not been identified. The patient denies suicidal thoughts.

In January 2021, due her grandmother developing a serious illness, the patient developed simple partial motor seizures in the form of right-sided tonic hemiconvulsions and facial muscles with head abduction to the right. During a seizure, the patient awakened and answered questions. She complained of severe pain, numbness in the right arm and leg. Convulsive seizures occurred every 2 hours. An EEG was recorded. Pronounced diffuse disturbances of cortical rhythmicity with a predominance of the average amplitude of beta activity in all leads without zonal differences. There was no alpha rhythm. A large number of bilaterally synchronous discharges of epileptiform activity were recorded in the form of "spike-wave" complexes (Fig. 9).

The patient was hospitalized in the epileptology department of the Republican Scientific and Practical Center for Mental Health. During the first day of hospitalization, an increase in the frequency of seizures was noted: seizures were noted every 2-5 minutes. Due to her serious condition, she was taken to the intensive care unit on a stretcher with status epilepticus, where she stayed from 02/04/2021 to 02/09/2021. Intensive therapy and monitoring were carried out in the department. After the treatment, the patient's condition improved slightly, she was transferred to the epilepsy department, where during the day there were seizures of the same nature with an interval between seizures of up to 10 minutes. The patient could not walk on her own, developed Todd's paralysis, and took food from the hands of the medical staff. In order to objectivize the process, ENMG of the upper and lower extremities was assigned. Conclusion: Signs of moderate damage to the distal parts of both m / tibial nerves of an axonal nature d> s (a history of habitual joint dislocations). There were no other lesions of the nerves of the lower extremities (table 1).

Tab. 1: Neuromyography of motor fibers

Names nerve level research	Amplitude of the M-response mV	Latent period, ms		Distance, mm	SRV motor, m/s	Residual latency, ms
		Distal	Proximal			
n. peroneus dex	08	6,2	12,7	34	46,6	3,68
	sin	1,9	6,4	37	41,6	4,91
n. tibialis dex	8,4	3,4	13,4	44	43,8	1,75
	sin	14,8	4,3	14,6	45	43,9
n.femoralis dex	8,2	2,2		13,5	61,4	
	sin	6,8	2,1	13,5	64,3	

MRI of the brain - a picture of moderate subatrophic changes in the cerebral hemispheres. No data were obtained for the presence of volumetric intracranial lesions. A single residual site in the left thalamus. In case of non-contrast ASL perfusion, there is an area of pronounced hyperperfusion on the left, near the postcentral sulcus, with a perifocal area of hypoperfusion in the left parietal lobe, areas of hyperperfusion in the right frontal and occipital lobes.

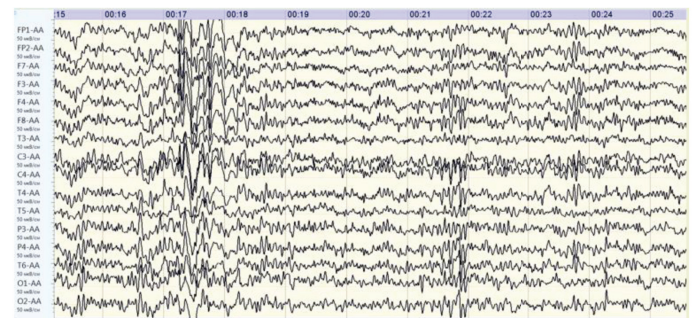


Fig. 9: EEG from 02/04/2021 upon admission to the hospital.

Considering the ineffectiveness of the ongoing anti-epileptic drug therapy: levetiracetam 1.0 x 2 times a day; depakine chrono 1.25 per day, severe pain in the right arm and leg, the patient was given gabapentin. With of the therapy, the patient's condition improved: the attacks began to occur much less frequently and had stopped by 02/19/21. The regression of the motor deficit began in a day, then the movements in the right limbs recovered. At the onset of remission it was noted moderate diffuse disturbances of cortical rhythm with a predominance of irregular, medium amplitude, zonally differentiated alpha rhythm on the EEG. In this situation, single flares were recorded in the form of low, bilaterally synchronous spikes in the frontal-central regions, more clearly pronounced on the right, as well as rare flashes of bilaterally synchronous alpha activity of low amplitude.

Attempts to stop levetiracetam or valproate resulted in increased seizure frequency. The patient was discharged from the hospital with a recommendation to continue taking levetiracetam 0.25 x 2 times a day; depakin chrono 0.5 x 2 times a day; gabapentin 0.6 x 4 times a day.

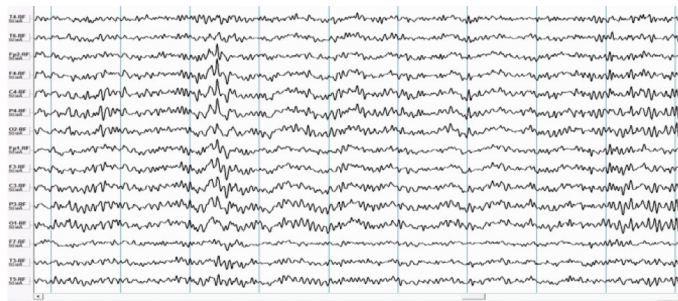


Fig. 10: EEG from 03/10/2021 upon the onset of remission and discharge from the hospital

Thus, the study showed that the patient has secondary generalized tonic-clonic and tonic convulsive seizures due to perinatal pathology with a history of developed pharmacoresistance to antiepileptic drugs. Treatment with AMSC BM significantly improved the patient's condition: generalized tonic-clonic and tonic seizures stopped. Remission was observed within 10 months after the repeated administration of AMSC KM. The patient recovered at the university and graduated and works as a teacher in a gymnasium. Against the background of a severe stressful situation, the patient developed the status of simple partial motor seizures in the form of right-sided tonic hemiclonvulsions and mimic muscles of the face and lips with head abduction to the right. The inclusion of gabapentin made it possible to stop the seizures and restore motor activity in the right limbs. In general, it can be assumed that treatment with autologous mesenchymal stem cells helps to overcome resistance to antiepileptic drug therapy.

Literature

- [1] Vermel A.E. Stem cells: general characteristics and prospects for their use in clinical practice. *Clinical Medicine* No. 1, 5 – 11, 2004.
- [2] Zenkov L.R. *Clinical electroencephalography (with elements of epileptology). A guide for doctors* / L.R. Zenkov. - 8th ed. - M.: MEDpressinform, 360, 2017.
- [3] Kvacheva Z.B., Votyakov V.I., Titov L.P. and other Stem cells. Prospects for their application in medicine. *Medical Journal* No. 4, 4-6, 2005.
- [4] Kissin, M. Ya. *Clinical epileptology*. - M.: GEOTAR - Media, 256, 2009].
- [5] Klimovich VB Immunomodulatory activity of mesenchymal stromal (stem) cells // *Medical Immunology* 2014, vol. 16, no. 2, 107-126.
- [6] Shershever A.S. *surgical treatment of epilepsy*. Yekaterinburg, 144s, 2005.
- [7] Chu K, Kim M, Jung KH, et al. Human neural stem cell transplantation reduces spontaneous recurrent seizures following pilocarpine-induced status epilepticus in adult rats. *Brain Res.*;1023(2):213 – 221, 2004.
- [8] Leal MM, Costa-Ferro ZS, Souza BS, Azevedo CM, Carvalho TM, Kaneto CM, et al. Early transplantation of bone marrow mononuclear cells promotes neuroprotection and modulation of inflammation after status epilepticus in mice by paracrine mechanisms. *Neurochem Res*; 39:259–68, 2014.

Received: 2021

Accepted: 2021